



[Authoritative facts](#) about the skin from the [New Zealand Dermatological Society Incorporated](#).

[Home](#) | [Acne and follicular disorders](#)

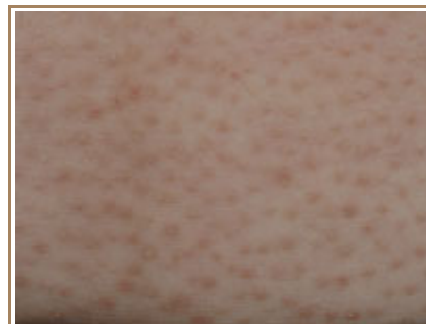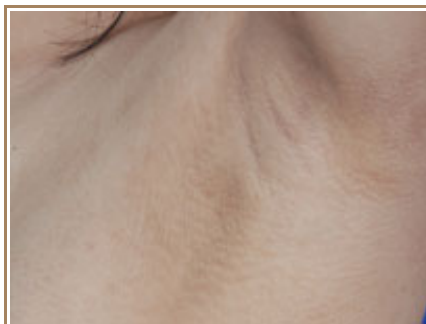
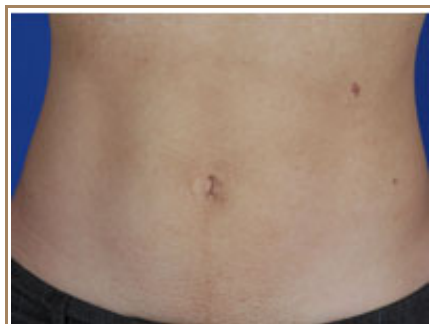Disseminate and recurrent infundibulofolliculitis

Disseminate and recurrent infundibulofolliculitis (DRIF) is also known as "Hitch and Lund disease" after the pair who first described this condition in 1968. It is a rare condition, mostly described as occurring in those of African descent.

Clinical presentation

This condition typically presents as a widespread, mildly itchy, follicular rash (arising within the hair follicle). It has been described as 'goose bumps through a magnifying glass'. The rash is slightly pink in appearance often with a brown, pigmented edge. The torso, neck and arms are most affected.

Infundibulofolliculitis



Histology

There is oedema (swelling) and lymphocytic infiltration (inflammation) around the infundibulum and basal region of the hair follicle. There is widening and proliferation of cells in the upper part of the follicle with variable amounts of scale formation. The direct immunofluorescence test is negative i.e. antibodies cannot be detected around the hair follicle.

Prognosis

Other than its appearance and in some, the itch, there are no serious consequences of this rash. Despite the name, not everyone has recurrent episodes, as a persistent rash is more usual. It generally resolves after some years.

Treatment

There is little response to [topical](#), intralesional or [systemic steroids](#), [antibiotics](#) such as [doxycycline](#), or [antihistamines](#). There are reports of improvement with oral vitamin A, [isotretinoin](#), and [PUVA](#).

Related information

References:

- Disseminate and recurrent infundibulo–folliculitis: report of a case. Hitch JM, Lund HZ. Arch Dermatol. 1968 Apr;97(4):432–5. [Medline](#).
- Disseminate and recurrent infundibulofolliculitis. Owen W, Wood C. Arch Dermatol. 1979; 115:174–5. [Medline](#).
- Disseminate and recurrent infundibulofolliculitis: response to psoralen plus UVA therapy. Ravikumar BC, Balachandran C, Sheno SD et al. Int J Dermatol. 1999 Jan; 38(1): 75–6. [Medline](#).

On DermNet NZ:**Other websites:**

- [Disseminate and Recurrent Infundibular Folliculitis](#) – emedicine dermatology

Books about skin diseases:

See the [DermNet NZ bookstore](#)

Author: Dr Ben Tallon, Dermatology Registrar, Greenlane Hospital, Auckland.

DermNet does not provide an on–line consultation service.

If you have any concerns with your skin or its treatment, see a [dermatologist](#) for advice.

Created 2006. Last updated 25 Dec 2006. © 2007 NZDS. Disclaimer.