



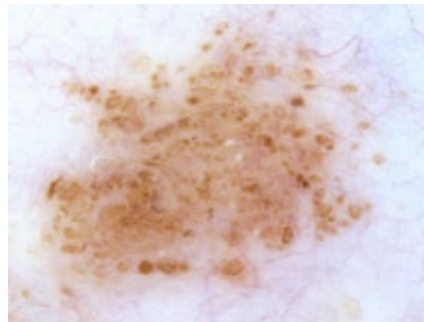
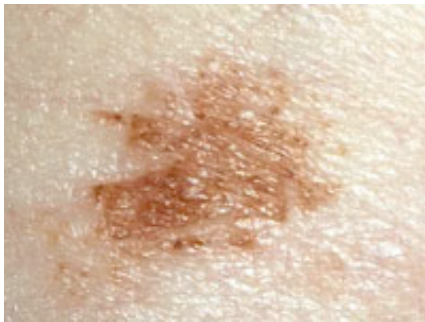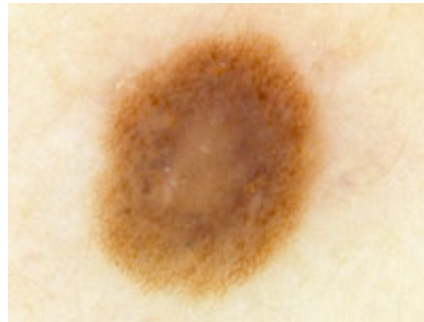
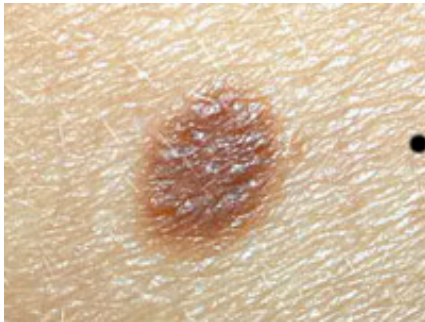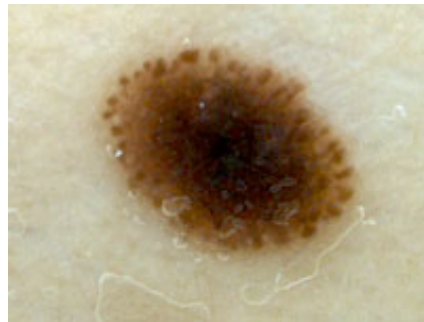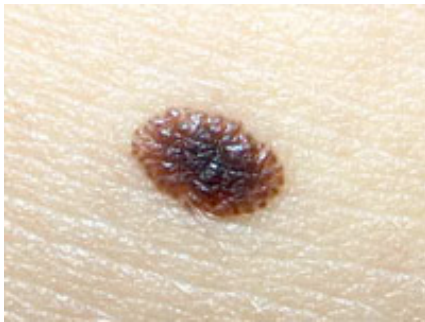
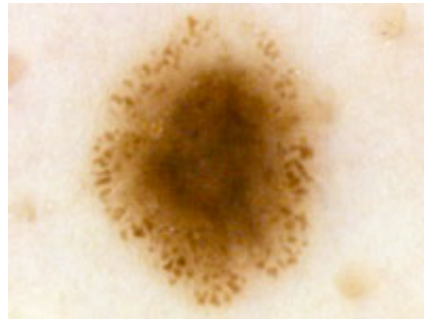
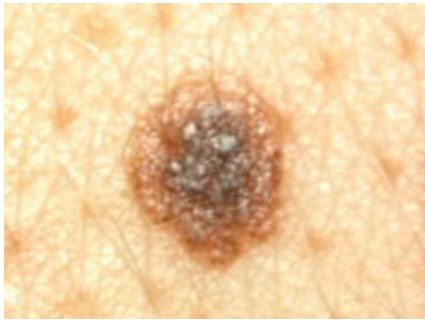[Authoritative facts](#) about the skin from the [New Zealand Dermatological Society Incorporated](#).

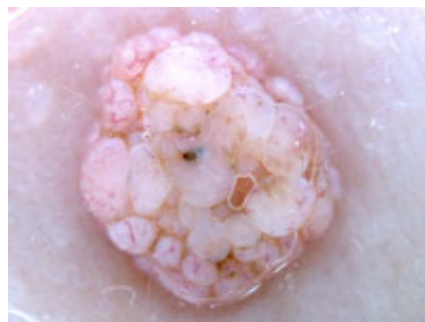
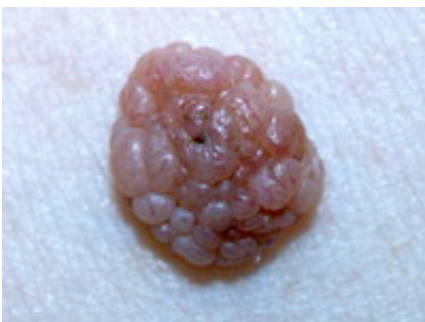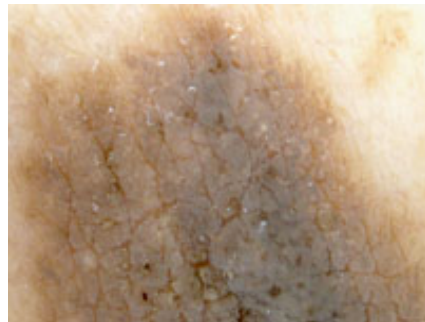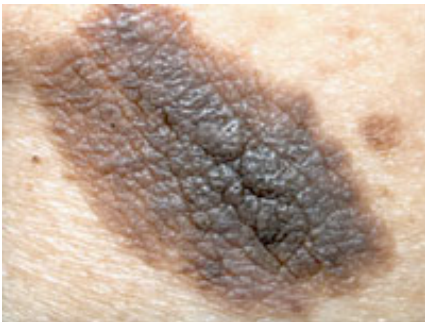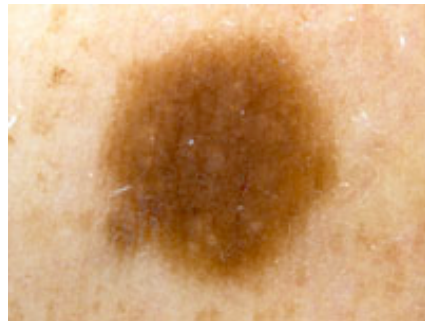
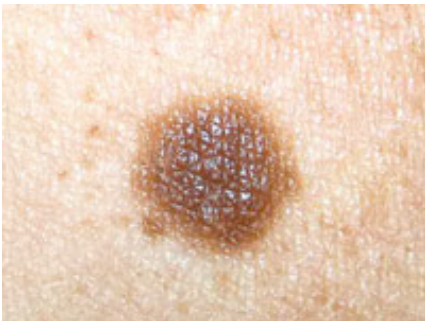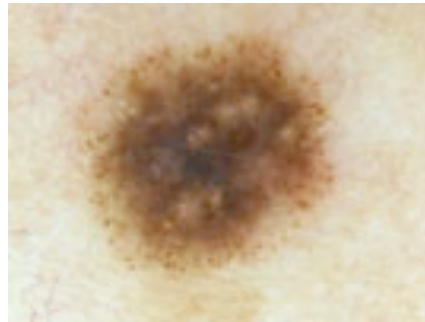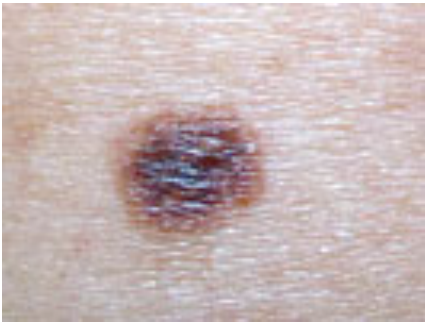
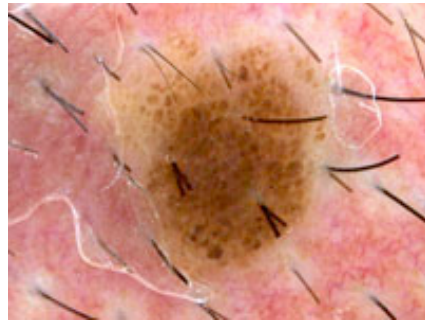
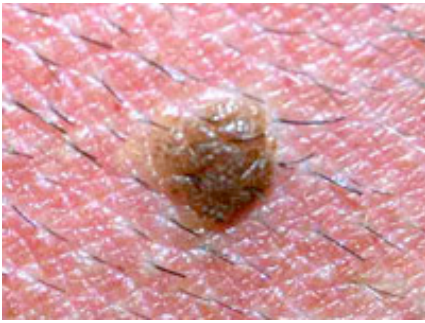
[Home](#) | [Dermoscopy course](#) | [New classification of melanocytic naevi](#) |  [Globular naevus images: PDF 164 KB](#)

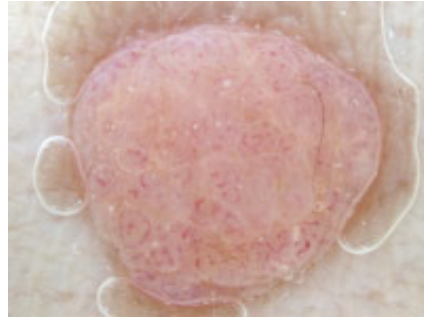
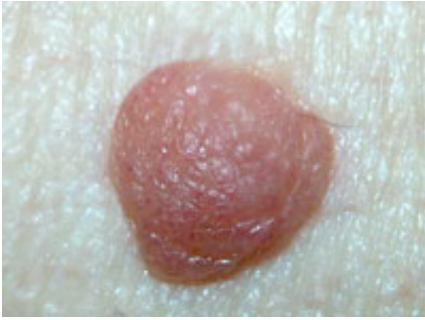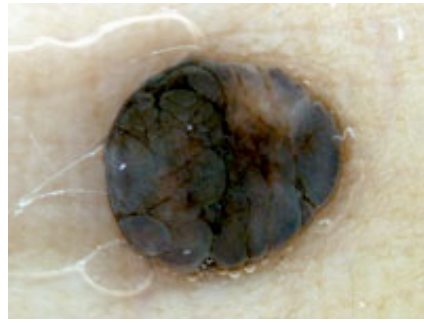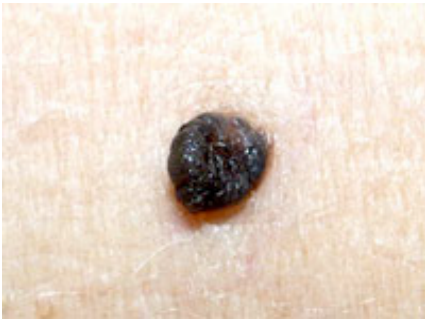
## Globular (congenital) naevus images

### Melanocytic naevi: dermoscopic globular pattern

---







#### Related information

#### References:

On DermNet NZ:

Other websites:

Books about skin diseases:

See the [DermNet NZ bookstore](#)

**Author:** Dr Amanda Oakley, Dermatology, Waikato Hospital, Hamilton.

DermNet does not provide an on-line consultation service.  
If you have any concerns with your skin or its treatment, see a [dermatologist](#) for advice.

Created 2008. Last updated 16 Nov 2008. © 2008 NZDS. Disclaimer.