



[Authoritative facts](#) about the skin from the [New Zealand Dermatological Society Incorporated](#).

[Home](#) | [Skin lesions](#)

Chondrodermatitis nodularis helicus

Chondrodermatitis nodularis chronica helicus (CNH) is a painful inflammatory condition affecting the ear. It is sometimes called Winkler disease.

CNH is most often seen in middle-aged or elderly men but may also affect women and younger adults. It results in a benign tender lump in the cartilaginous portion of the ear. The helix (thus "helicus") is the top of the ear. Strictly speaking the condition should be called "chondrodermatitis nodularis chronica antehelicus" when it affects the inner rim of cartilage.

The affected area may only be a few millimetres wide, but to lie on it causes exquisite discomfort. There is often a tiny central core which may discharge a small amount of scaly material. It may persist for months or sometimes years, and may be confused with a skin cancer.

What is the cause of CNH?

The cause of CNH appears to be pressure between the head and the pillow at night. CNH occurs in people who sleep predominantly on one side. It can be precipitated by minor trauma, such as tight headgear or a telephone headset, or by exposure to cold. Reduction in the local blood supply of the ear by a [chilblain](#) or with aging prevents adequate healing.

Chondrodermatitis nodularis

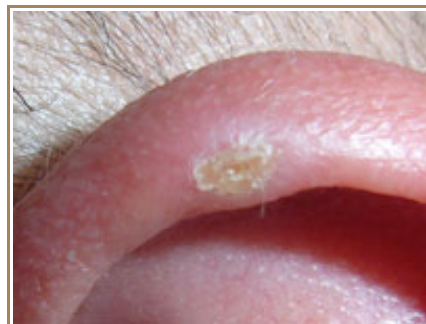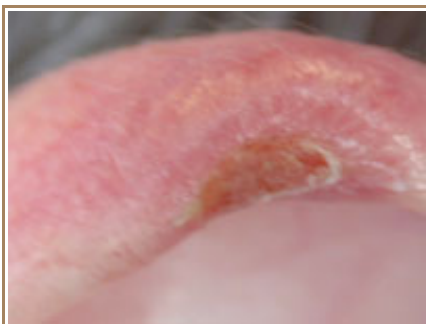

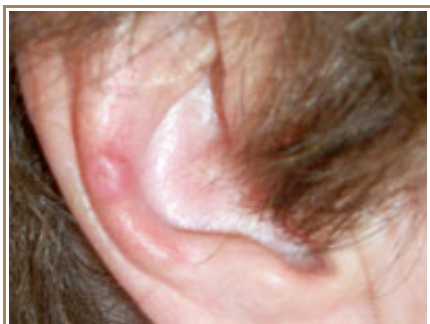
Image provided by Dr Trevor Evans

Treatment

- It is important to avoid sleeping on the affected ear. Check your pillow is soft and consider fashioning a 'hole' in it so there is no pressure on the painful spot. Try to sleep evenly on both sides.
- Using foam rubber or a bath sponge, you can make a CNH ear protector that can be worn all night. Hold it in place with an elastic headband. Alternatively, you can purchase one from a dermatology supplies company.
- Your dermatologist may be able to arrange for a protective made-to-measure silicone splint.
- Wear a warm hat over the ears when outside in the cold and wind.
- If the CNH is ulcerated, apply an antibiotic ointment under a light dressing; plain petroleum jelly may also be effective.
- Your doctor may treat the lesion with a cortisone injection or freeze it with [liquid nitrogen](#) to promote

healing.

- [Collagen](#) may be injected under the skin above the cartilage to provide a protective layer.
- Surgical treatment may be required ([excision biopsy](#)). Unfortunately CNH has a 10–30% recurrence rate after surgery.
 - The affected area may be scraped out by [curettage](#), and left to heal by secondary intention.
 - The overlying skin is peeled back and the underlying abnormal cartilage excised, leaving a small scar.
 - The ulcer may be excised by punch biopsy, with full thickness skin grafting.

Related information

On DermNet NZ:

- [Skin lesions](#)

Other websites:

- [Chondrodermatitis nodularis](#) - emedicine dermatology, the on-line textbook.

DermNet does not provide an on-line consultation service.

If you have any concerns with your skin or its treatment, see a [dermatologist](#) for advice.

Created 1997. Last updated 18 Nov 2007. © 2007 NZDS. Disclaimer.