DermNet NZ

Authoritative facts about the skin from the New Zealand Dermatological Society Incorporated.

Kaposi sarcoma

Kaposi sarcoma is a disease of blood vessels that was considered very rare before the start of the AIDS pandemic. AIDS is due to infection with human immunodeficiency virus (HIV).

There are four types of Kaposi sarcoma:

- The classic type of Kaposi sarcoma affects elderly men of Mediterranean and Middle European descent and in men in Sub-Saharan Africa.
- HIV-associated Kaposi sarcoma mainly affects men who have sex with men.
- Endemic or African Kaposi sarcoma arises in some parts of Africa in children and young adults.
- Iatrogenic Kaposi sarcoma is due to drug treatment causing immune suppression.

Classic Kaposi sarcoma is rare and unassociated with HIV infection. It most often arises in middle-aged to elderly men of Mediterranean or Jewis descent (less than 10% are women), particularly if they come from a rural environment. They have a higher than expected rate of diabetes mellitus.

In the United States, Kaposi sarcoma was particularly common in the 1980s especially amongst HIV-positive men who had sex with men. It occurs less frequently in intravenous drug users and is rare in women, haemophiliacs or their sexual partners. HIV-associated Kaposi sarcoma is more common in women in some parts of Africa. It has become less common in the US and Europe because of effective HAART treatment for HIV disease.

African Kaposi sarcoma is becoming more prevalent with the rise in HIV infection. It is one of the most common forms of cancer, especially in children, in Uganda and Zambia.

Iatrogenic Kaposi sarcoma is a particular concern for organ transplant patients, especially in geographic areas associated with high levels of infection with KSHV. Most have the virus prior to transplantation, but the drugs causes it to reactivate.

What is Kaposi sarcoma due to?

Kaposi sarcoma is associated with:

- Infection with Kaposi sarcoma herpes virus (KSHV). This virus is also called human herpes virus 8. It is most often found in men who have sex with men but it can also occur in heterosexuals. Data is emerging that non-sexual modes of transmission can occur, possibly via saliva or arthropod bites.
- Production of certain cytokines or cell signalling proteins
- Genetic factors
- Hormonal factors

Researchers sometimes classify Kaposi sarcoma as a reactive hyperplasia and sometimes as a neoplasm (cancer); at times they may consider it multicentric and other times metastatic.

KSHV may lie dormant, or replicate and cause disease. As well as causing Kaposi sarcoma, it may also be the cause of some forms of non-Hodgkin lymphoma and Casteleman disease.

How does it present?

Kaposi sarcoma presents as red to purplish spots (macules) and raised bumps (papules and nodules) anywhere on the skin or mucous membranes. Initially, the lesions are small and painless but they can ulcerate and become painful. There are various forms.

- Localised nodular
- Locally aggressive
- Generalised lymphadenopathic
- Patch stage
- Localised plaques
- Exophytic lesions
- Infiltrative plaques
- Disseminated cutaneous and visceral disease
- Telangiectatic
- Keloidal
- Ecchymotic
- Lymphangioma-like / cavernous disease

Kaposi sarcoma often starts as flat patches one or both lower legs, often in association with lymphoedema. The patches evolve into plaques, nodule or scaly tumours.

Kaposi sarcoma in association with HIV infection may develop at any time during the course of illness. Generally, the greater the immunosuppression (e.g. with CD4 cell counts less than 200/mm3) the more extensive and aggressive the Kaposi sarcoma will be.

Kaposi sarcoma lesions can also occur internally; in the gut, lungs, genitals, lymphatic system and elsewhere. These internal lesions may cause symptoms e.g. discomfort with swallowing, bleeding, shortness of breath, swollen legs, etc.

Kaposi sarcoma

Patch stage

Plaque stage

Classic disease

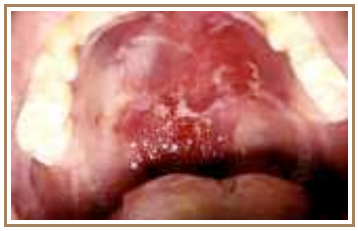

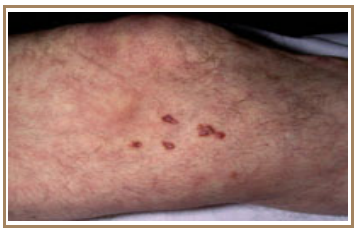

Plaque stage

More images of Kaposi sarcoma ...

Diagnosis

The appearance of Kaposi sarcoma lesions is often typical but a skin biopsy of a lesion allows a definite diagnosis. The tumour is made up of spindle cells and vascular structures with a characteristic pattern of clefting

(vascular slits).

Blood tests may show no abnormality, depending whether there are associated disorders such as AIDS. Anaemia may arise if there is bleeding. KSHS assays or antibody titres to KSHS are difficult to interpret.

Staging and prognosis

There have been various attempts to classify Kaposi sarcoma, depending on whether it is localised or disseminated in the skin, and if there is lymph node or internal organ involvement. The degree of immunosuppression present may also be used in staging systems.

Kaposi sarcoma has a variable course. Some patients develop only a few minor skin lesions whilst others have much more extensive external and internal disease. The latter lesions may result in fatal complications, e.g., from bleeding, obstruction or perforation of an organ. Kaposi sarcoma is not curable, but it can be treated and its symptoms controlled.

Treatment

In HIV disease, if the lesions are not widespread or troublesome, often the best approach is simply to treat the underlying HIV infection with highly active antiretroviral drug combinations that suppress HIV replication (HAART). These drugs reduce the frequency of Kaposi sarcoma and may also prevent its progression or the development of new lesions. It is not yet clear why this approach works; one opinion is that the improvement in immune function results in reduced levels of tumour growth-promoting proteins.

Iatrogenic Kaposi sarcoma may improve or clear if it is possible to stop immune suppressive medication.

The choice of more specific treatment depends largely on the extent of the disease.

Treating localised lesions

Small, localised lesions are generally only treated if they are painful or they are causing cosmetic problems. It should be noted that lesions tend to recur after local treatments. Treatments include:

- Cryotherapy with liquid nitrogen
- Radiotherapy. This is most useful for classic Kaposi sarcoma and is less effective for HIV-associated disease.
- Surgical excision of individual nodules.
- Laser therapy, using pulsed dye laser or pulsed carbon dioxide laser.
- Injection with anti-cancer drugs such as vinblastine
- Topical application of alitretinoin gel (Panretin). This drug is not yet available in New Zealand.

Treating extensive or internal lesions with systemic therapy

A combination of anti-cancer drugs are given, but at lower than usual dosages if there is immunosuppression.

Other chemotherapy treatments that are used in some international centres include bleomycin, etoposide, paclitaxel, docetaxel and liposomal forms of the standard anti-cancer drugs, doxorubicin or daunorubicin. &squo;Liposomal' means that the drugs are coated in small fat bubbles, or liposomes which allows better absorption, hopefully resulting in fewer side effects.

Immunotherapy includes the use of interferon-alpha and imiquimod, sirolimus and thalidomide.

Clinical trials into a wide range of other therapies are ongoing. Some examples of these are:

- Photodynamic therapy (a combination of a photosensitiser and light energy)
- Isotretinoin (a vitamin-A derivative)
- Cytokine inhibitors
- The pregnancy hormone, human chorionic gonadotropin (HCG); Kaposi sarcoma lesions disappear in

some women when they become pregnant.

- Ganciclovir, cidovir and foscarnet (antiviral medications) have been recently reported to result in lower rates of Kaposi sarcoma amongst those being treated for CMV retinitis (inflammation of the retina caused by cytomegalovirus) and are currently being studied. Aciclovir, another antiviral, has been tried, but does not appear to work.

Related information

References:

- Schwartz RA, Micali G, Nasca MR, Scuderi L. Kaposi sarcoma: a continuing conundrum. J Am Acad Dermatol. 2008 Aug;59(2):179-206. Medline

On DermNet:

- Human immunodeficiency virus

Other websites:

- Kaposi's Sarcoma - Medline Plus
- Kaposi Sarcoma - emedicine dermatology, the online textbook

Author: Jane Morgan MB ChB MRCP FACSHP, Health Waikato, Private Bag 3200, Hamilton. Updated by Amanda Oakley, Health Waikato 2008.

DermNet does not provide an on-line consultation service.
If you have any concerns with your skin or its treatment, see a dermatologist for advice.

Created 2003. Last updated 28 Sep 2008. © 2008 NZDS. Disclaimer.